



Corticosteroid Injections For the Family Physician Knee and Subacromial Techniques

Kaitlin Minnehan, MD and Sanath Srivastava, MD
MaineHealth Sports Medicine

Objectives

- Understand the indications, risks, and contraindications for landmark-guided corticosteroid injections of the knee and subacromial space
- Identify the key anatomic landmarks required to safely perform landmark-guided knee and subacromial corticosteroid injections
- Practice proper technique for knee and subacromial corticosteroid injections through hands-on simulation



Knee injections and Aspirations

Why Would One Perform a Knee Aspiration or Injection?

Aspiration

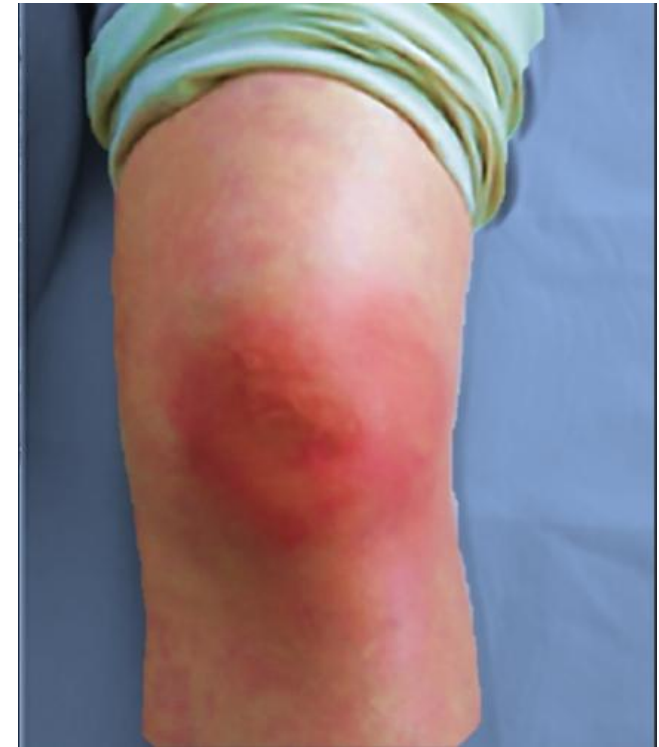- Red or swollen joint
 - Septic joint
 - Lyme
 - Gout/CPPD
 - Rheumatologic Disease

Corticosteroid Injection

- Osteoarthritis
- Gout/CPPD
- Rheumatoid Arthritis

Why Would One NOT Perform a Knee Injection?

- Overlying Cellulitis
 - Allergy to instilled medication
 - Uncontrolled bleeding diathesis
 - DOACs/well-monitored warfarin generally ok
 - Uncontrolled diabetes (A1c>9%)
 - Uncontrolled infection
- Important to mention for consent: Risk of bleeding, infection, inflammation



<https://ar.inspiredpencil.com/pictures-2023/septic-arthritis>

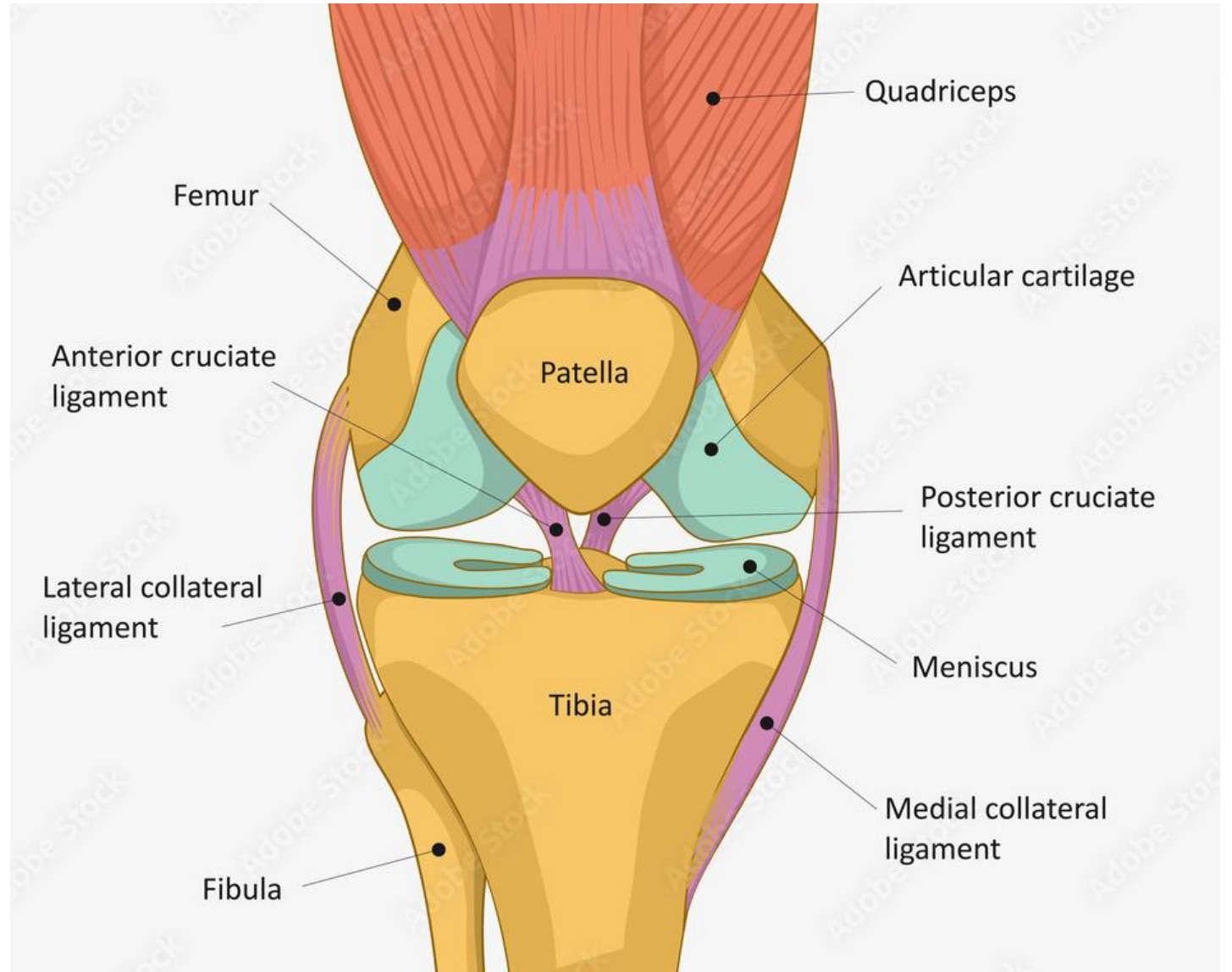
Knee Anatomy

Bones

Tendons

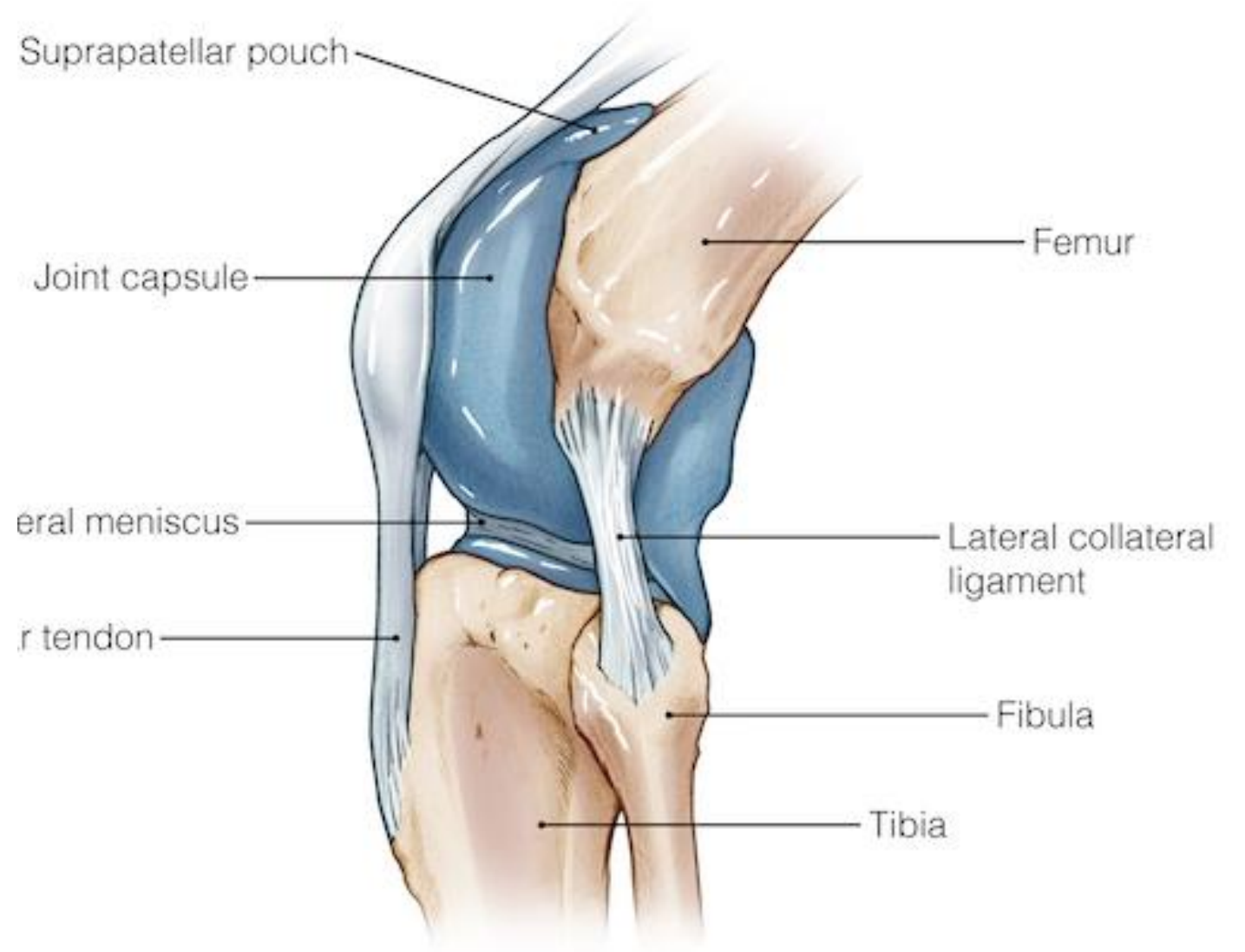
Ligaments

Soft tissue



<https://stock.adobe.com/images/human-knee-joint-anatomy-knee-tendons-anatomical-diagram/480090632>

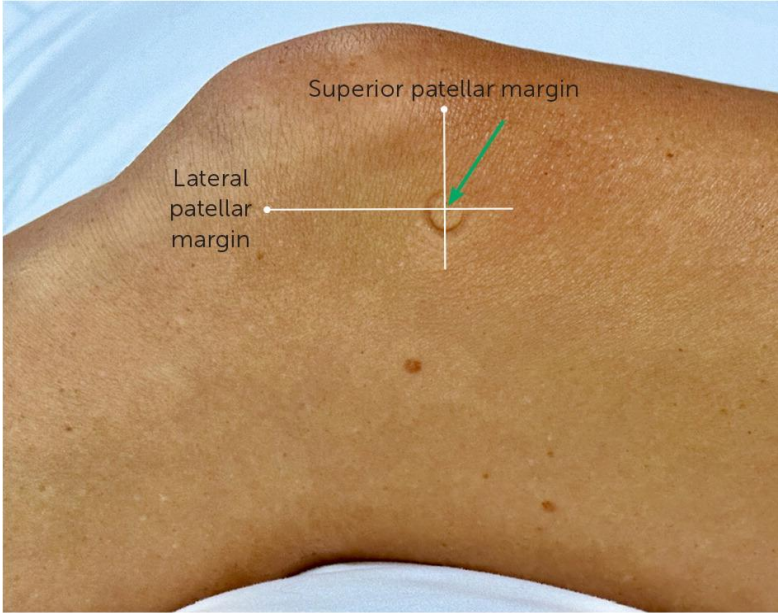
Joint Capsule



<https://anatomy.lexmedicus.com.au/collection/knee>

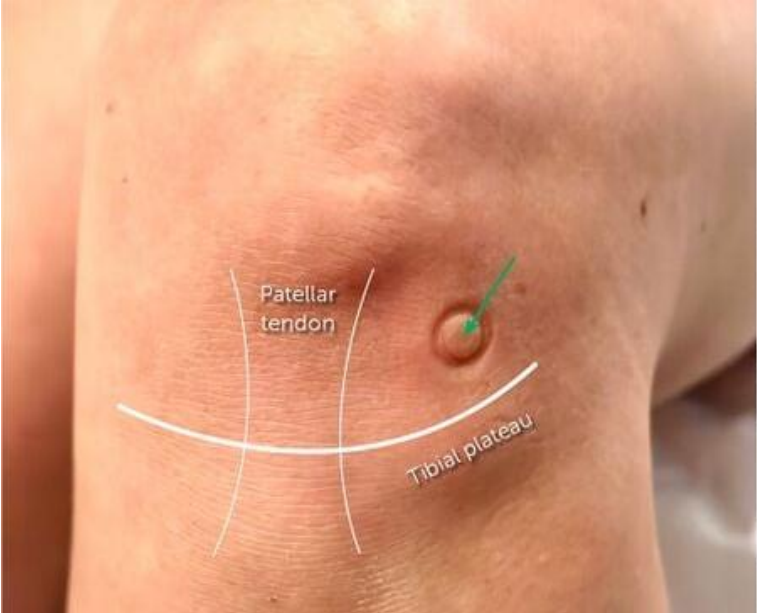
Three Different Approaches

Suprapatellar



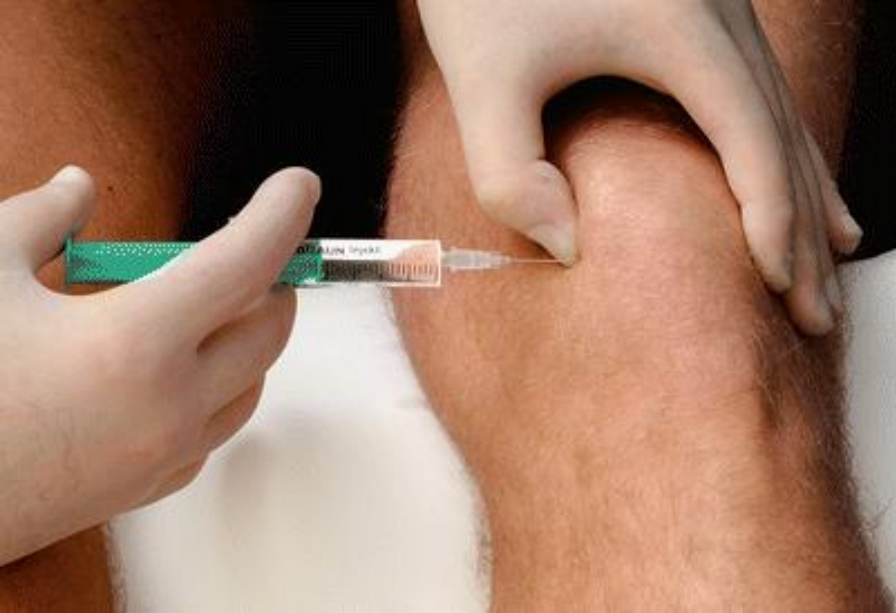<https://www.aafp.org/pubs/afp/issues/2024/0100/hip-and-knee-injections.html>

Infrapatellar



https://wikism.org/Knee_Joint_Injection

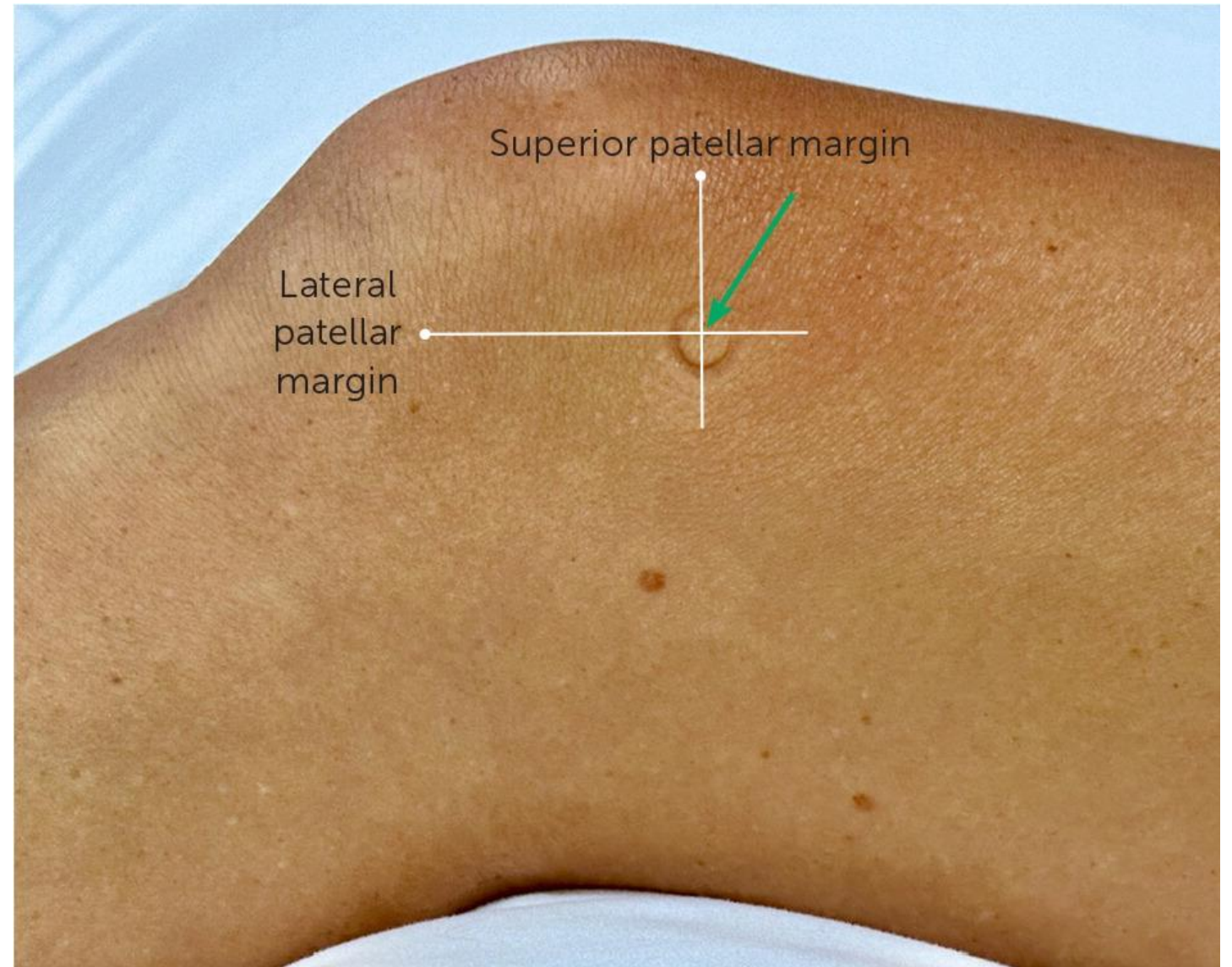
Parapatellar



<https://www.slideserve.com/quanda/arthrocentesis-and-joint-injection-for-the-internist>

Superolateral Approach

- Palpate injection site
- Sterilize
- Inject anesthetic
- Inject Corticosteroid solution
- Gauze and band aid



<https://www.aafp.org/pubs/afp/issues/2024/0100/hip-and-knee-injections.html>

Procedure

Prep

- Sterile gloves (optional)
- Cleaning swab/solution
- Ethyl chloride (optional)
- Gauze
- Band-aid

Injection

- Pre-injection
 - 3cc 1% Lidocaine with 25G 1.5 inch needle
- Aspiration
 - 18G 1.5 inch needle with large syringe
- Corticosteroid injection
 - 4cc 1% Lidocaine + 40mg methylprednisolone
 - 21-22G 1.5-2 inch needle

Pitfalls/Adverse effects

- Bony resistance
- Tight joint
- Elevations in blood glucose
- "Steroid flare"



Practice time!



Subacromial/Subdeltoid Corticosteroid Injections

Subacromial/Subdeltoid Steroid Injections

Indications

- Rotator cuff impingement and tendinosis
- Subdeltoid bursitis
- Adhesive capsulitis

Contraindications

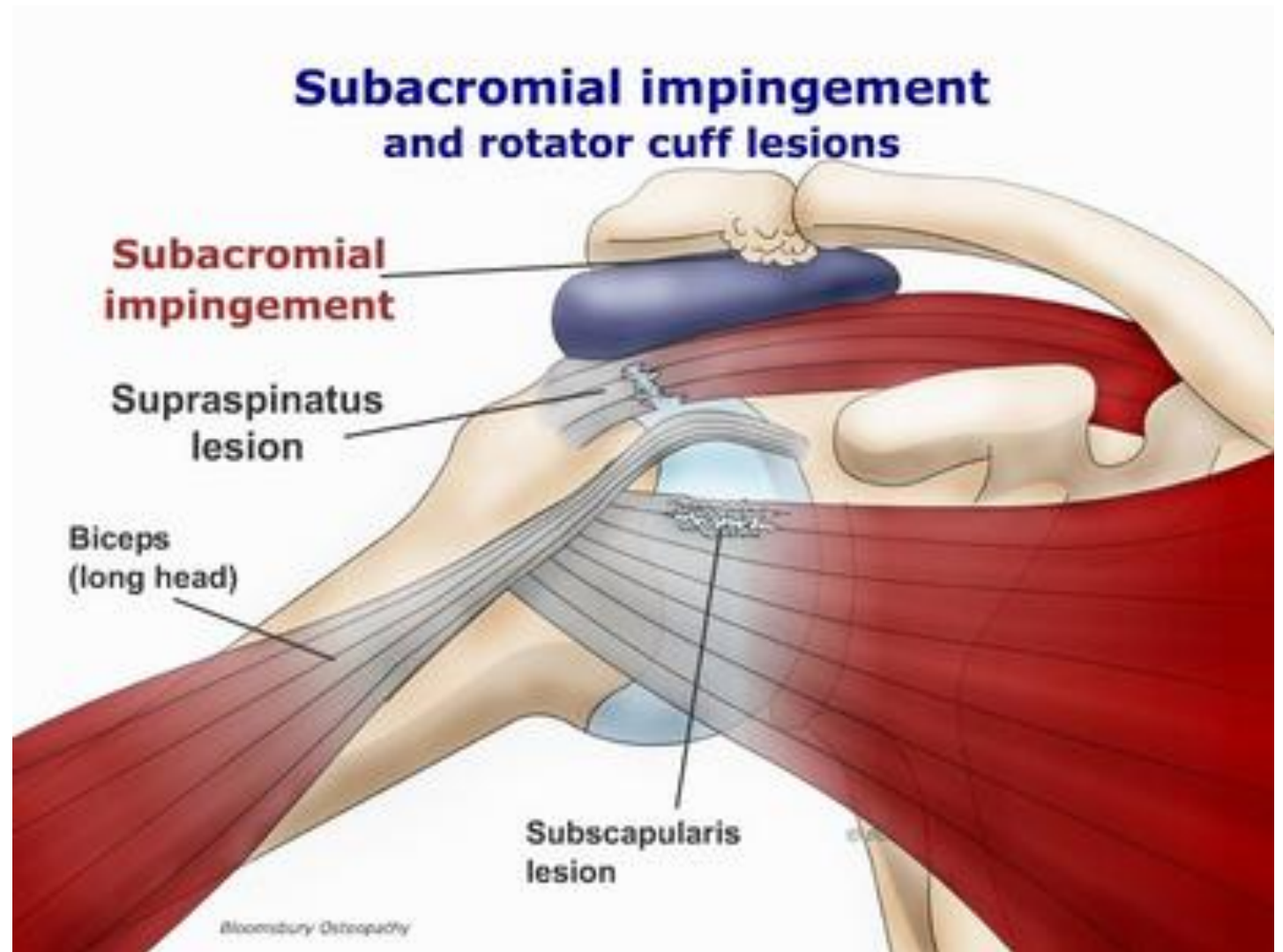
- Full-thickness rotator cuff tear (relative)
- Other-mentioned above
 - Cellulitis, allergy, uncontrolled DM etc

Shoulder Anatomy

Bones

Rotator cuff tendons

Soft tissue



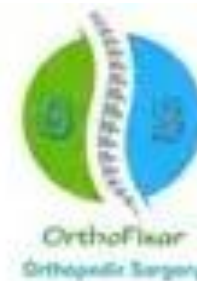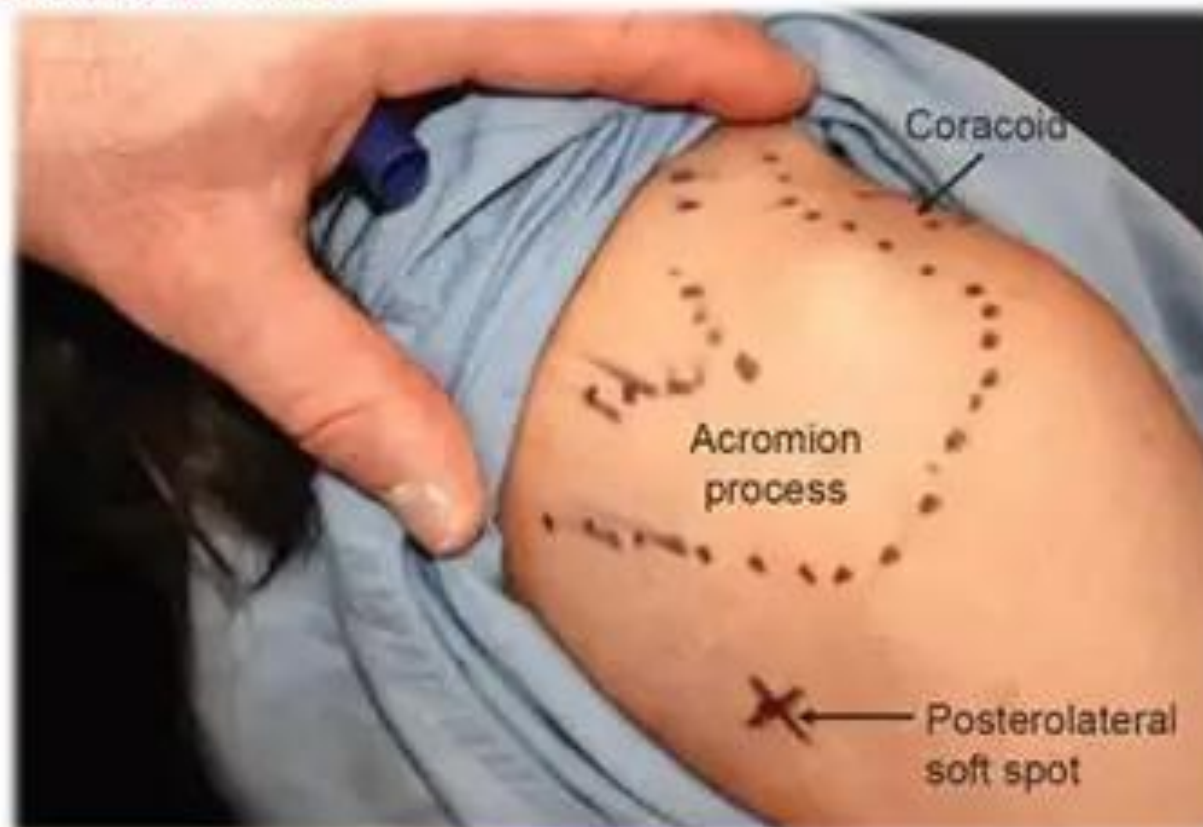
<https://physiocure.in/subacromial-impingement-syndrome/>

Technique

- Palpate injection site
- Sterilize
- Inject anesthetic
- Inject Corticosteroid solution
- Gauze and band aid

Cautions and Pitfalls

Posterolateral Portal



<https://orthofixar.com/orthopedic-procedure/shoulder-injection-technique/>

Take home points

- Aspiration is very important for diagnosis of a swollen joint
- Shoulder and knee injections are a very safe form of pain relief
- Try sterile gloves while learning to help palpate landmarks
- Palpation is the most important step for success
- 3 cc of lidocaine and 4 cc of lidocaine plus 40 mg methylprednisolone
- Ok to readjust the needle -> pull back without completely removing needle



Thank you!

References

- Webb CW, McLeod G, Nuti R. Injections of the Hip and Knee. Am Fam Physician. 2024 Jan;109(1):61-70.
- Tallia AF, Cardone DA. Diagnostic and therapeutic injection of the shoulder region. Am Fam Physician. 2003 Mar 15;67(6):1271-8.